Neoplasia

Dr. Aso Ahmad Abdulla

Board Certified General and Laparoscopic Surgeon

FIBMS, MBChB

College of Medicine

University of Garmian

Session 9 Neoplasia I

Objectives By the end of the module you should be able to:

1) Define neoplasia.
2) Describe the alterations to DNA which cause neoplasia.
3) Describe clonality of neoplasms.
4) Describe the alterations in growth control
- Increased cell proliferation
- Decreased cell death
- Longer cellular lifespan
- Altered growth factors/hormones and receptors
- Altered cell-cell interactions

5) Describe and compare benign and malignant tumours
- Growth characteristics
- Cytological features

6) Define dysplasia.
7) Distinguish between in-situ and invasive malignancy.
8) Describe the basic histological types of benign and malignant neoplasms

- Adenoma
- Papilloma
- Carcinoma adeno, squamous, transitional
- Benign mesenchymal tumours eg leiomyoma, lipoma
- Sarcomas eg leiomyosarcoma
- Gliomas
- Lymphomas

- Germ cell tumours
- Tumours of the white cells

leukaemia
myeloma

INTRODUCTION

Cancer is the second leading cause of death in the United States; only cardiovascular diseases exact a higher toll. Even more agonizing than the associated mortality is the emotional and physical suffering inflicted by neoplasms. Patients and the public often ask, “When will there be a cure for cancer?” The answer to this simple question is difficult, because cancer is not one disease but rather many disorders that share a profound growth dysregulation. Some cancers, such as Hodgkin lymphoma, are **highly curable**, whereas others, such as cancer of the pancreas, are virtually always fatal. The only hope for controlling cancer lies in learning more about its pathogenesis, and great strides have been made in understanding the molecular basis of cancer.

The term ‘neoplasia’ means new growth; the new growth produced is called ‘neoplasm’ or ‘tumour’. However, all ‘new growths’ are not neoplasms since examples of new growth of tissues and cells also exist in the processes of embryogenesis, regeneration and repair, hyperplasia and hormonal stimulation. The proliferation and maturation of cells in normal adults is controlled as a result of which some cells proliferate throughout life (labile cells), some have limited proliferation (stable cells), while others do not replicate (permanent cells). On the other hand, neoplastic cells lose control and regulation of replication and form an abnormal mass of tissue.

Therefore, satisfactory definition of a neoplasm or tumour is ‘a mass of tissue formed as a result of abnormal, excessive, uncoordinated, autonomous and purposeless proliferation of cells even after cessation of stimulus for growth which caused it’.

The branch of science dealing with the study of neoplasms or tumours is called oncology (oncos=tumour, logos=study). Neoplasms may be ‘benign’ when they are slow-growing and localised without causing much difficulty to the host, or ‘malignant’ when they proliferate rapidly, spread throughout the body and may eventually cause death of the host. The common term used for all malignant tumours is cancer.

All tumours, benign as well as malignant, have 2 basic components:

'Parenchyma' comprised by proliferating tumour cells; parenchyma determines the nature and evolution of the tumour.

'Supportive stroma' composed of fibrous connective tissue and blood vessels; it provides the framework on which the parenchymal tumour cells grow.

The tumours derive their nomenclature on the basis of the parenchymal component comprising them. The suffix *'-oma'* is added to denote benign tumours. Malignant tumours of epithelial origin are called *carcinomas,* while malignant mesenchymal tumours are named *sarcomas* (*sarcos* = fleshy)

However, some cancers are composed of highly undifferentiated cells and are referred to as *undifferentiated malignant tumours*.

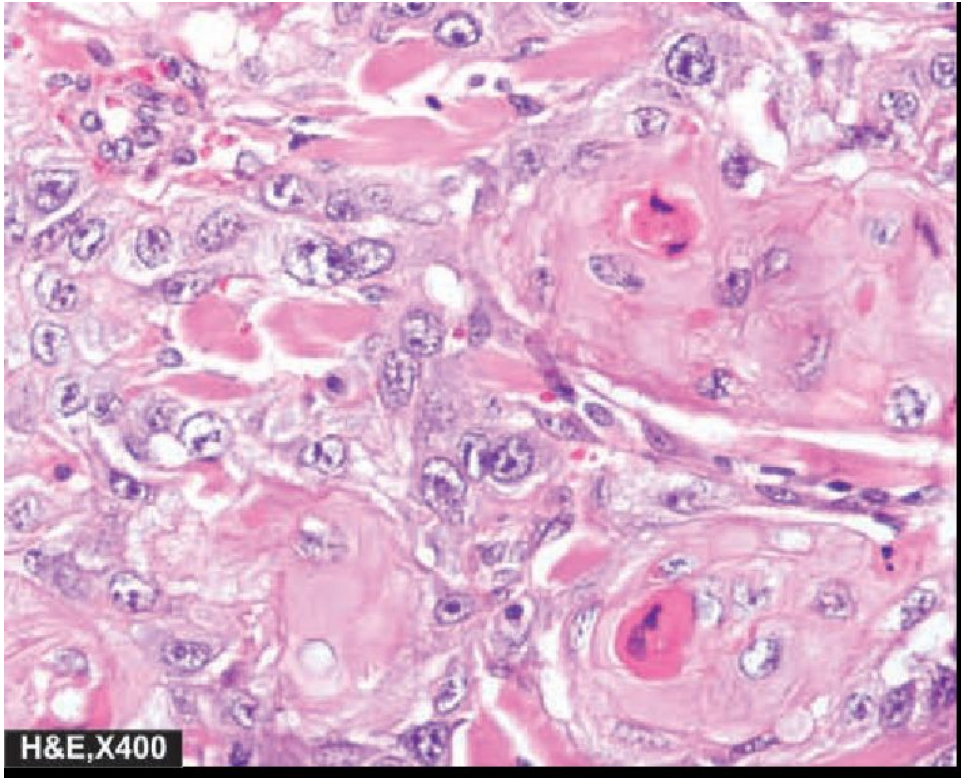

A. SQUAMOUS CELL CARCINOMA

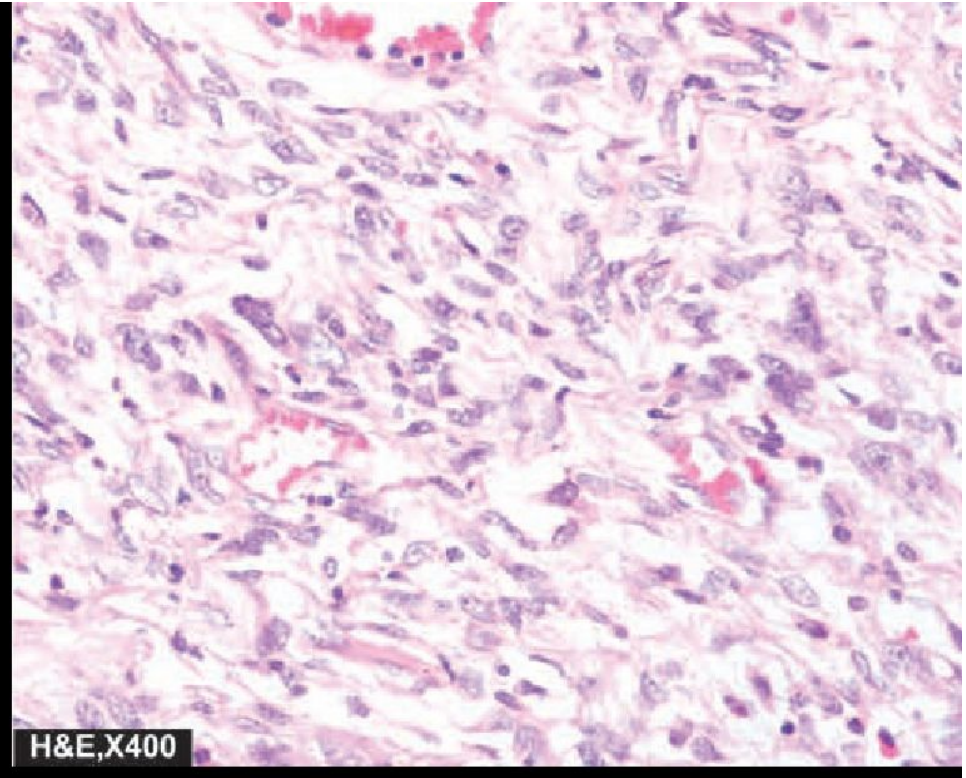

B. FIBROSARCOMA

•

Papilloma of the colon with finger-like projections into the lumen.

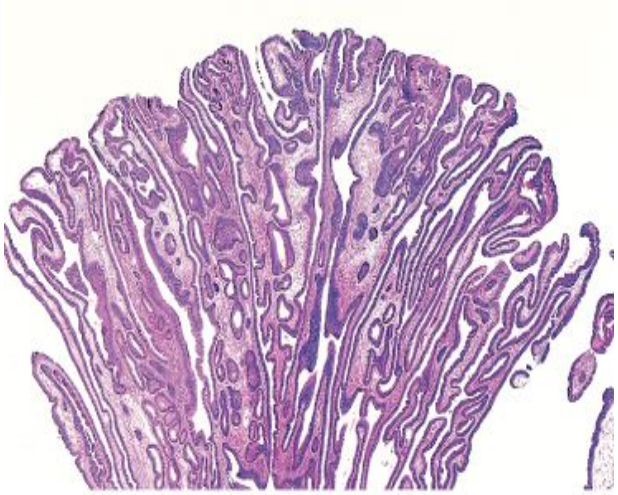

© Elsevier 2005

Fig. 6.1 Colonic polyp. This glandular tumor is seen projecting into the colonic lumen. The polyp is attached to the mucosa by a distinct stalk.

Although, this broad generalisation regarding nomenclature of tumours usually holds true in majority of instances, some examples contrary to this concept are: *melanoma* for carcinoma of the melanocytes, *hepatoma* for carcinoma of the hepatocytes, *lymphoma* for malignant tumour of the lymphoid tissue, and *seminoma* for malignant tumour of the testis. *Leukaemia* is the term used for cancer of blood forming cells.

Nomenclature of Tumors

Tissue of Origin	Benign	Malignant
Connective tissue and derivatives	Fibroma	Fibrosarcoma
	Lipoma	Liposarcoma
	Chondroma	Chondrosarcoma
	Osteoma	Osteogenic sarcoma
Endothelium and related cell types		
Blood vessels	Hemangioma	Angiosarcoma
Lymph vessels	Lymphangioma	Lymphangiosarcoma
Mesothelium		Mesothelioma
Brain coverings	Meningioma	Invasive meningioma
Blood cells and related cell types		
Hematopoietic cells		Leukemias
Lymphoid tissue		Lymphomas
Muscle		
Smooth	Leiomyoma	Leiomyosarcoma
Striated	Rhabdomyoma	Rhabdomyosarcoma

Skin		
Stratifiedsquamous	Squamous cell papilloma	Squamous cell or epidermoid carcinoma
Basal cells of skin or adnexa		Basal cell carcinoma
Tumors of melanocytes	Nevus	Malignant melanoma
Epithelial lining of glands or ducts	Adenoma	Adenocarcinoma
	Papilloma	Papillary carcinomas
	Cystadenoma	Cystadenocarcinoma
Lung	Bronchial adenoma	Bronchogenic carcinoma
Kidney	Renal tubular adenoma	Renal cell carcinoma
Liver	Liver cell adenoma	Hepatocellular carcinoma
Bladder	Urothelial papilloma	Urothelial carcinoma
Placenta	Hydatidiform mole	Choriocarcinoma
Testicle		Seminoma
		Embryonal carcinoma

Comparison between a benign tumor of the myometrium (leiomyoma) and a malignant tumor of similar origin (leiomyosarcoma).

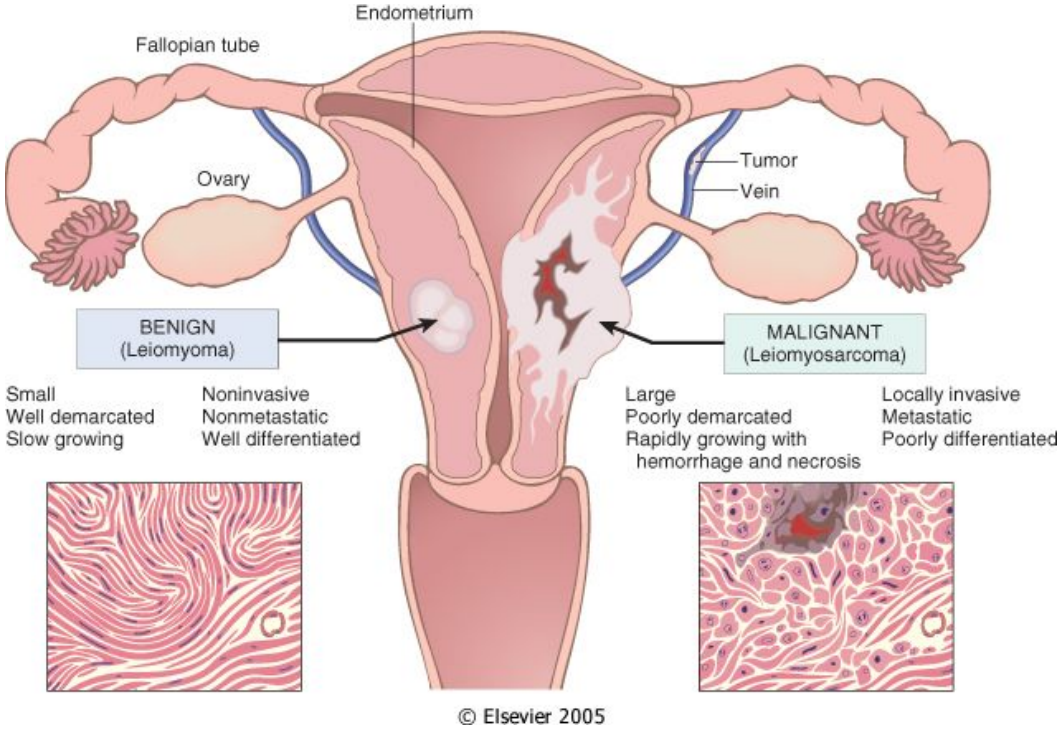

SPECIAL CATEGORIES OF TUMOURS.

Following categories tumours are examples which defy the generalisation in nomenclature given above:

1. Mixed tumours. When two types of tumours are combined in the same tumour, it is called a mixed tumour. For example:
i) Adenosquamous carcinoma is the combination of adenocarcinoma and squamous cell carcinoma in the endometrium.

ii) Adenoacanthoma is the mixture of adenocarcinoma and benign squamous elements in the endometrium.

Iii) Carcinosarcoma is the rare combination of malignant tumour of the epithelium (carcinoma) and of mesenchymal tissue (sarcoma) such as in thyroid.

iv) Collision tumour is the term used for morphologically two different cancers in the same organ which do not mix with each other.

v) Mixed tumour of the salivary gland (or pleomorphic adenoma) is the term used for benign tumour having combination of both epithelial and mesenchymal tissue elements.

Important

2. Teratomas.

These tumours are made up of a mixture of various tissue types arising from totipotent cells derived from the three germ cell layers—ectoderm, mesoderm and endoderm.

Most common sites for teratomas are ovaries and testis (*gonadal teratomas*). But they occur at *extra-gonadal sites* as well, mainly in the midline of the body such as in the head and neck region, mediastinum, retroperitoneum, sacrococcygeal region etc. Teratomas may be *benign or mature* (most of the ovarian teratomas) or *malignant or immature* (most of the testicular teratomas).

Gross appearance of an opened cystic teratoma of the ovary. Note the presence of hair, sebaceous material, and tooth.

© Elsevier 2005

3. Blastomas (Embryomas).

Blastomas or embryomas are a group of malignant tumours which arise from embryonal or partially differentiated cells which would normally form blastema of the organs and tissue during embryogenesis. These tumours occur more frequently in infants and children (under 5 years of age) and include some examples of tumours in this age group:

neuroblastoma, nephroblastoma (Wilms' tumour), hepatoblastoma, retinoblastoma, medulloblastoma, pulmonary blastoma.

4. Hamartoma.

Hamartoma is benign tumour which is made of mature but disorganised cells of tissues indigenous to the particular organ e.g. hamartoma of the lung consists of mature cartilage, mature smooth muscle and epithelium. Thus, all mature differentiated tissue elements which comprise the bronchus are present in it but are jumbled up as a mass.

5. Choristoma.

Choristoma is the name given to the ectopic islands of normal tissue. Thus, choristoma is heterotopia but is not a true tumour, though it sounds like one.

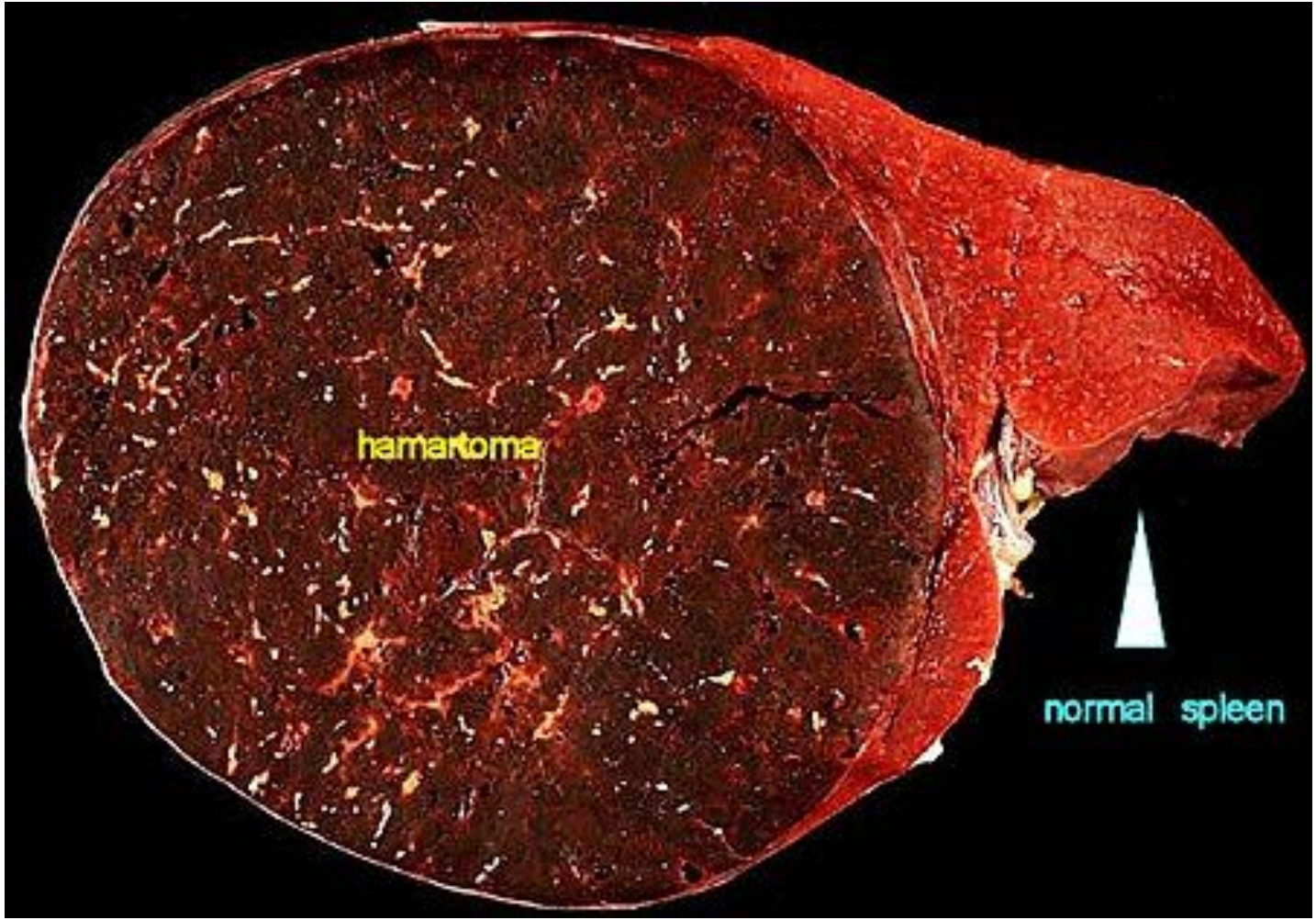
hamartoma
normal spleen

CHARACTERISTICS OF TUMOURS

Majority of neoplasms can be categorised clinically and morphologically into benign and malignant on the basis of certain characteristics listed below. there is a wide variation in the degree of deviation from the normal in all the tumours.

The characteristics of tumours are described under the following headings:

I. Rate of growth
II. Cancer phenotype and stem cells
III. Clinical and gross features
IV. Microscopic features
V. Local invasion (Direct spread)
VI. Metastasis (Distant spread).

Contrasting Features of Benign and Malignant Tumours.

Feature	Benign	Malignant
I. CLINICAL AND GROSS FEATURES		
1. Boundaries	Encapsulated or well-circumscribed	Poorly-circumscribed and irregular
2. Surrounding tissue	Often compressed	Usually invaded
3. Size	Usually small	Often larger
4. Secondary changes	Occur less often	Occur more often
II. MICROSCOPIC FEATURES		
1. Pattern	Usually resembles the tissue of origin closely	Often poor resemblance to tissue of origin
2. Basal polarity	Retained	Often lost
3. Pleomorphism	Usually not present	Often present
4. Nucleo-cytoplasmic ratio	Normal	Increased
5. Anisonucleosis	Absent	Generally present
6. Hyperchromatism	Absent	Often present
7. Mitoses	May be present but are always typical mitoses	Mitotic figures increased and are generally atypical and abnormal
8. Tumour giant cells	May be present but without nuclear atypia	Present with nuclear atypia
9. Chromosomal abnormalities	Infrequent	Invariably present
10. Function	Usually well maintained May be retained,	lost or become abnormal
III. GROWTH RATE	Usually slow	Usually rapid
IV. LOCAL INVASION	Often compresses the surrounding tissues without invading or infiltrating them	Usually infiltrates and invades the adjacent tissues
V. METASTASIS	Absent	Frequently present
VI. PROGNOSIS	Local complications	Death by local and metastatic complications

BENIGN MALIGNANT

EPITHELIAL

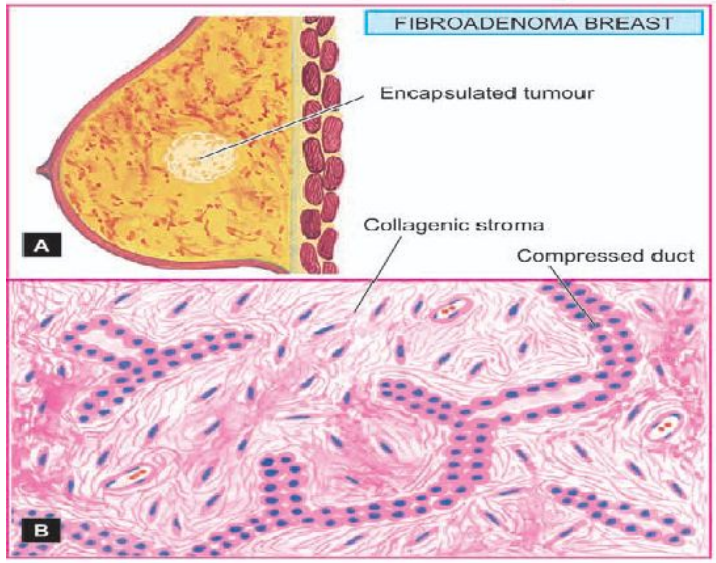

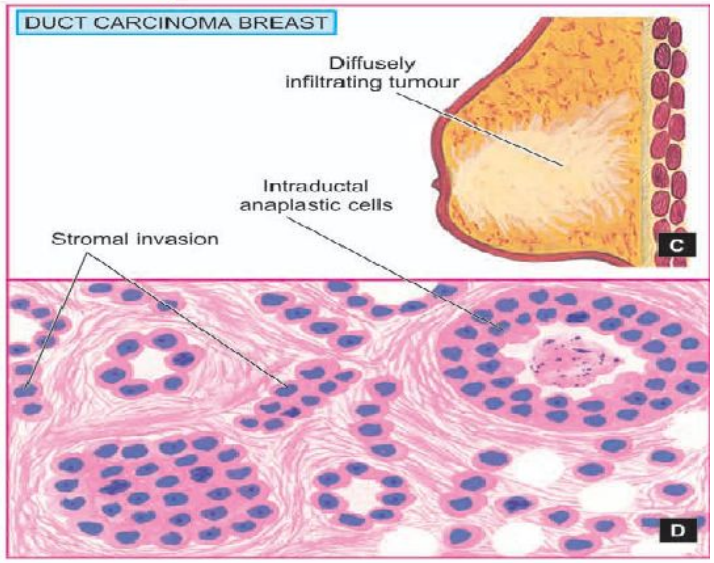

MESENCHYMAL

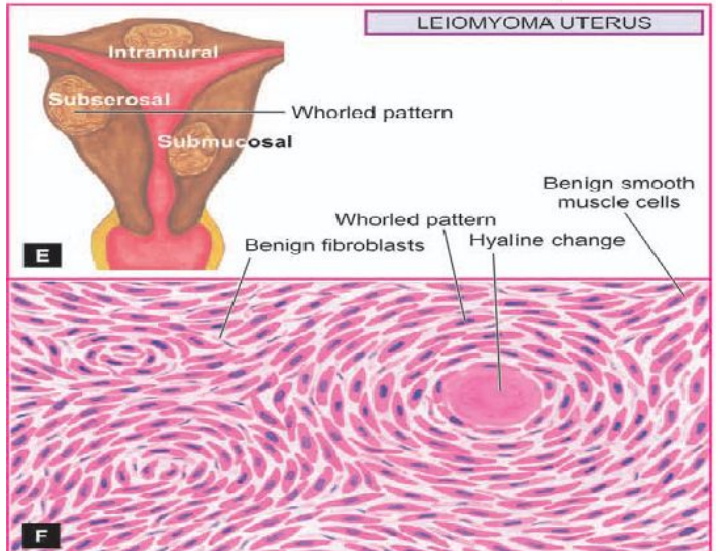

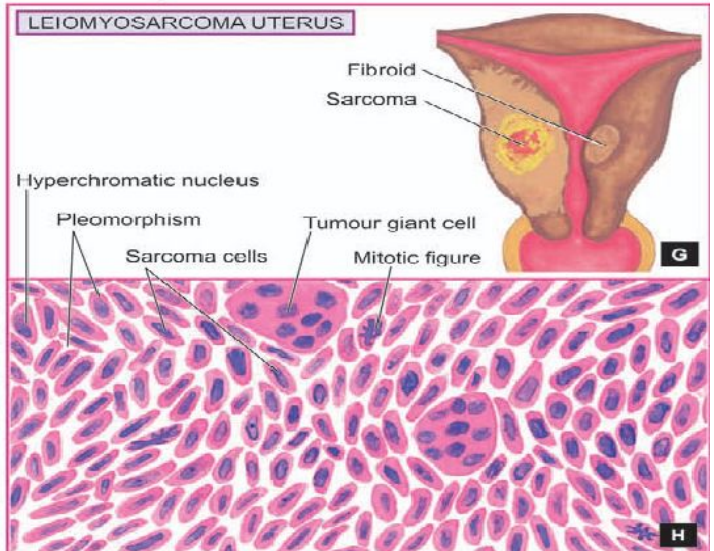

Benign tumor (adenoma) of the thyroid. Note the normal-looking (well-differentiated), colloid-filled thyroid follicles

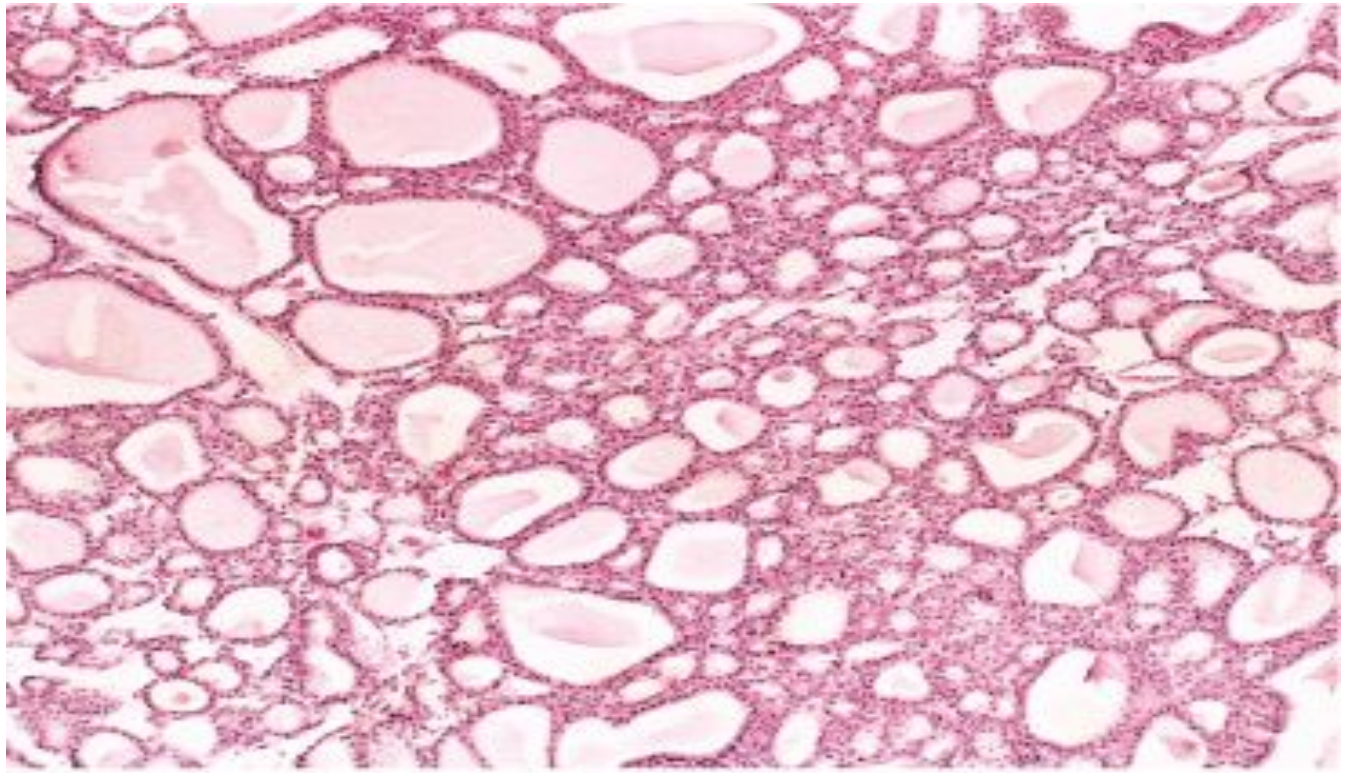

© Elsevier 2005

I. RATE OF GROWTH

Important

The tumour cells generally proliferate more rapidly than the normal cells. In general, benign tumours grow slowly and malignant tumours rapidly. However, there are exceptions to this generalisation. The rate at which the tumour enlarges depends upon 2 main factors:

1. Rate of cell production, growth fraction and rate of cell loss

Rate of growth of a tumour depends upon 3 important parameters:
i) doubling time of tumour cells,
ii) number of cells remaining in proliferative pool (growth fraction), and
iii) rate of loss of tumour cells by cell shedding.

In general, malignant tumour cells have increased mitotic rate (doubling time) and slower death rate i.e. the cancer cells do not follow normal controls in cell cycle and are immortal.
If the rate of cell division is high, it is likely that tumour cells in the centre of the tumour do not receive adequate nourishment and undergo ischaemic necrosis

2. Degree of differentiation

Secondly, the rate of growth of malignant tumour is directly proportionate to the degree of differentiation. Poorly differentiated tumours show aggressive growth pattern as compared to better differentiated tumours. Some tumours, after a period of slow growth, may suddenly show spurt in their growth due to development of an aggressive clone of malignant cells. On the other hand, some tumours may cease to grow after sometime. Rarely, a malignant tumour may disappear spontaneously from the primary site, possibly due to necrosis caused by good host immune attack, only to reappear as secondaries elsewhere in the body e.g. choriocarcinoma, malignant melanoma.

The regulation of tumour growth is under the control of growth factors secreted by the tumour cells.
Out of various growth factors, important ones modulating tumour biology are listed below and discussed later:

i) Epidermal growth factor (EGF)
ii) Fibroblast growth factor (FGF)
iii) Platelet-derived growth factor (PDGF)
iv) Colony stimulating factor (CSF)
v) Transforming growth factors-β (TGF-β)
vi) Interleukins (IL)
vii) Vascular endothelial growth factor (VEGF)

II. CANCER PHENOTYPE AND STEM CELLS

Normally growing cells in an organ are related to the neighbouring cells—they grow under normal growth controls, perform their assigned function and there is a balance between the rate of cell proliferation and the rate of cell death including cell suicide (i.e. apoptosis). Thus normal cells are socially desirable. However, cancer cells exhibit antisocial behaviour as under:

i) Cancer cells disobey the growth controlling signals in the body and thus *proliferate rapidly*.

ii) Cancer cells escape death signals and achieve *immortality*.

iii) Imbalance between cell proliferation and cell death in cancer causes *excessive growth*.

iv) Cancer cells lose properties of differentiation and thus perform *little or no function*.

v) Due to loss of growth controls, cancer cells are genetically unstable and develop *newer mutations*.

vi) Cancer cells overrun their neighbouring tissue and *invade locally*.

vii) Cancer cells have the ability to travel from the site of origin to other sites in the body where they colonise and establish *distant metastasis*.

III. CLINICAL AND GROSS FEATURES

Clinically, benign tumours are generally slow growing, and depending upon the location, may remain asymptomatic (e.g. subcutaneous lipoma), or may produce serious symptoms (e.g. meningioma in the nervous system).

On the other hand, malignant tumours grow rapidly, may ulcerate on the surface, invade locally into deeper tissues, may spread to distant sites (metastasis), and also produce systemic features such as weight loss, anorexia and anemia. In fact, two of the cardinal clinical features of malignant tumours are: **invasiveness and metastasis**

%100 If's tumor

گرنگن

Very important

Gross appearance of benign and malignant tumours may be quite variable and the features may not be diagnostic on the basis of gross appearance alone. However, certain distinctive features characterise almost all tumours compared to neighbouring normal tissue of origin—they have a different colour, texture and consistency. Gross terms such as papillary, fungating, infiltrating, haemorrhagic, ulcerative and cystic are used to describe the macroscopic appearance of the tumours.

Benign tumours are generally spherical or ovoid in shape. They are encapsulated or well-circumscribed, freely movable, more often firm and uniform, unless secondary changes like haemorrhage or infarction

Malignant tumours, on the other hand, are usually irregular in shape, poorly-circumscribed and extend into the adjacent tissues. Secondary changes like haemorrhage, infarction and ulceration are seen more often. Sarcomas typically have fish-flesh like consistency while carcinomas are generally firm

IV. MICROSCOPIC FEATURES

For recognising and classifying the tumours, the microscopic characteristics of tumour cells are of greatest importance. These features which are appreciated in histologic sections are as under:

1. microscopic pattern;
2. cytomorphology of neoplastic cells (differentiation and anaplasia)
3. tumour angiogenesis and stroma
4. inflammatory reaction.

1. Microscopic Pattern

The tumour cells may be arranged in a variety of patterns in different tumours as under:

The ***epithelial tumours*** generally consist of acini, sheets, columns or cords of epithelial tumour cells that may be arranged in solid or papillary pattern .

The ***mesenchymal tumours*** have mesenchymal tumour cells arranged as interlacing bundles, fasicles or whorls, lying separated from each other usually by the intercellular matrix substance such as hyaline material in leiomyoma

cartilaginous matrix in chondroma, osteoid in osteosarcoma, reticulin network in soft tissue sarcomas

Certain tumours have ***mixed patterns*** e.g. teratoma arising from totipotent cells, pleomorphic adenoma of salivary gland (mixed salivary tumour), fibroadenoma of the breast, carcinosarcoma of the uterus and various other combinations of tumour types.

Haematopoietic tumours such as leukaemias and lymphomas often have none or little stromal support.

Generally, most benign tumours and low grade malignant tumours *reduplicate* the normal structure of origin more closely so that there is little difficulty in identifying and classifying such tumours . However, **anaplastic tumours** differ greatly from the arrangement in normal tissue of origin of the tumour and may occasionally pose problems in classifying the tumour

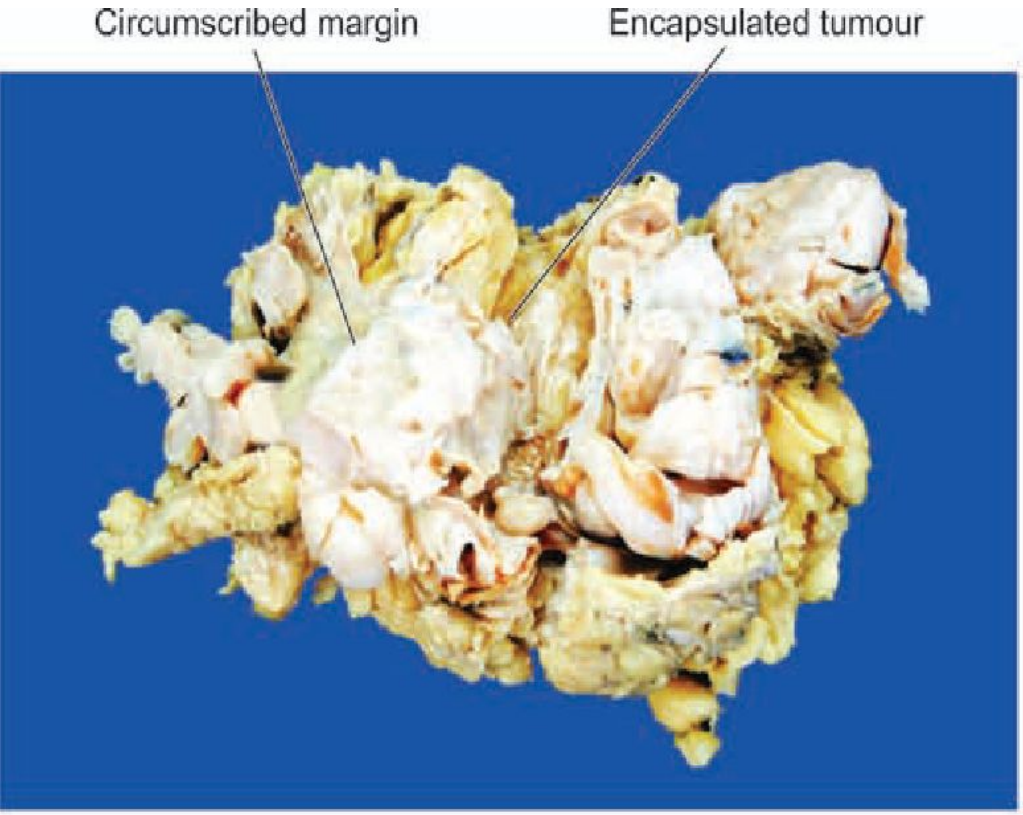

A. FIBROADENOMA BREAST

Benign

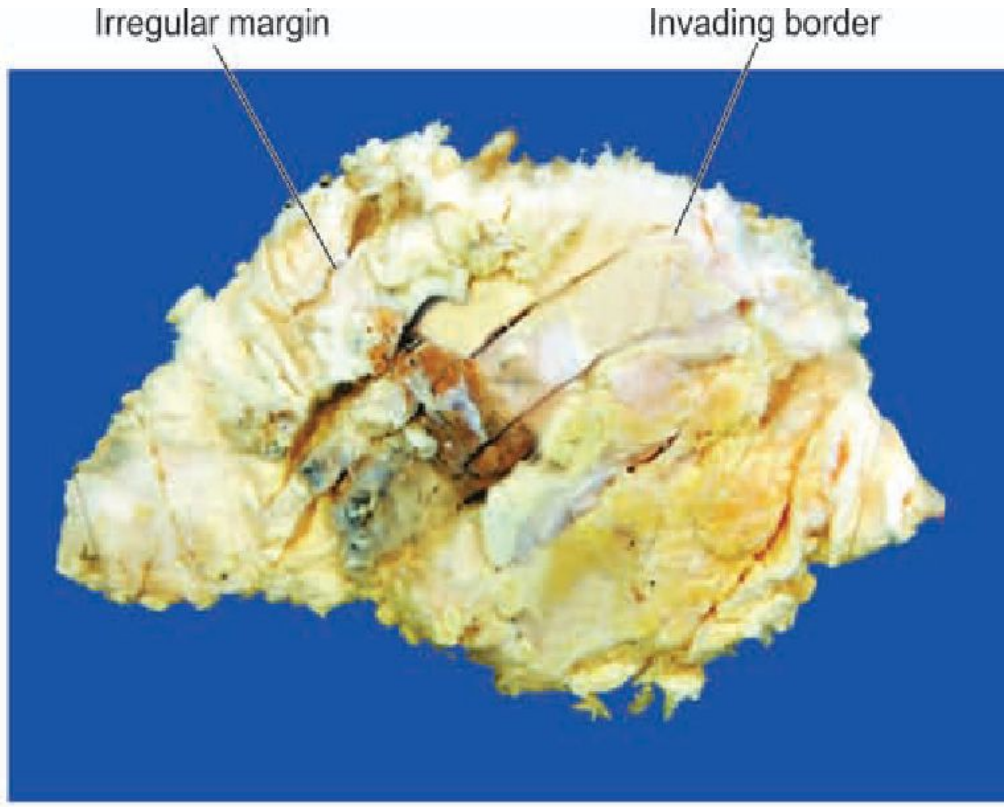

B. INFILTRATING CARCINOMA BREAST

Malignant

2. Cytomorphology of Neoplastic Cells (Differentiation and Anaplasia)

The neoplastic cell is characterised by morphologic and functional alterations, the most significant of which are *'differentiation' and 'anaplasia'.*
Differentiation is defined as the extent of morphological and functional resemblance of parenchymal tumour cells to corresponding normal cells. If the deviation of neoplastic cell in structure and function is minimal as compared to normal cell, the tumour is described as *'well-differentiated'* such as most benign and low-grade malignant tumours.
'***Poorly differentiated', 'undifferentiated'* or *'dedifferentiated***' are synonymous terms for poor structural and functional resemblance to corresponding normal cell.

Anaplasia is lack of differentiation and is a characteristic feature of most malignant tumours. Depending upon the degree of differentiation, the extent of anaplasia is also variable i.e. poorly differentiated malignant tumours have high degree of anaplasia.

As a result of anaplasia, noticeable morphological and functional alterations in the neoplastic cells are observed.

Anaplastic tumor of the skeletal muscle (rhabdomyosarcoma). Note the marked cellular and nuclear pleomorphism, hyperchromatic nuclei, and tumor giant cells

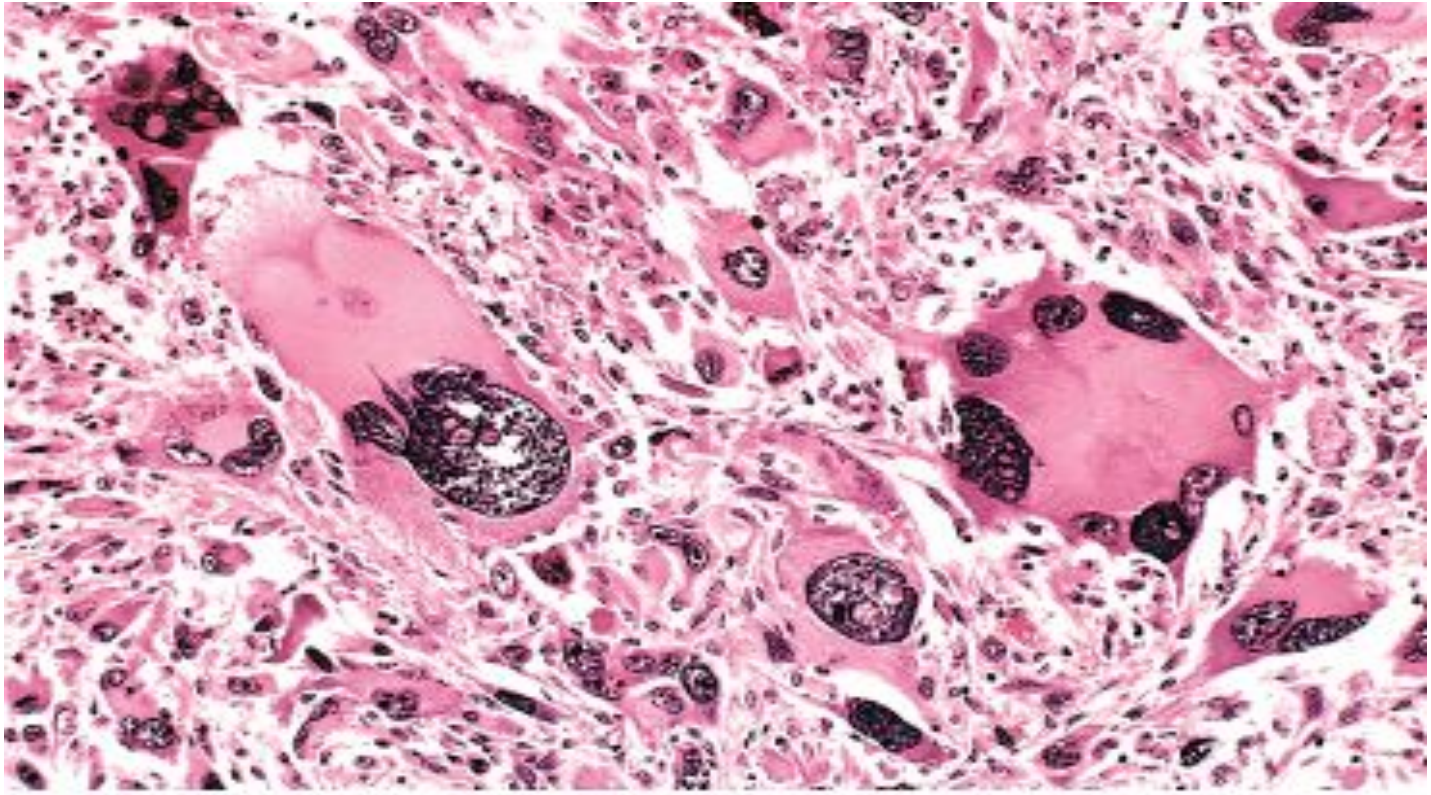

© Elsevier 2005

i) ***Loss of polarity.*** Normally, the nuclei of epithelial cells are oriented along the basement membrane which is termed as basal polarity. This property is based on cell adhesion molecules, particularly selectins. Early in malignancy, tumour cells lose their basal polarity so that the nuclei tend to lie away from the basement membrane

ii) ***ii) Pleomorphism****.* The term pleomorphism means variation in size and shape of the tumour cells. The extent of cellular pleomorphism generally correlates with the degree of anaplasia. Tumour cells are often bigger than normal but in some tumours they can be of normal size or smaller than normal .

iii) ***N:C ratio.*** Generally, the nuclei of malignant tumour cells show more conspicuous changes. Nuclei are enlarged disproportionate to the cell size so that the nucleocytoplasmic ratio is increased from normal 1:5 to 1:1

iv) ***Anisonucleosis.*** Just like cellular pleomorphism, the nuclei too, show variation in size and shape in malignant tumour cells .

v) ***Hyperchromatism****.* Characteristically, the nuclear chromatin of malignant cell is increased and coarsely clumped. This is due to increase in the amount of nucleoprotein resulting in dark-staining nuclei, referred to as hyperchromatism.

vi) Nucleolar changes. Malignant cells frequently have a prominent nucleolus or nucleoli in the nucleus reflecting increased nucleoprotein synthesis

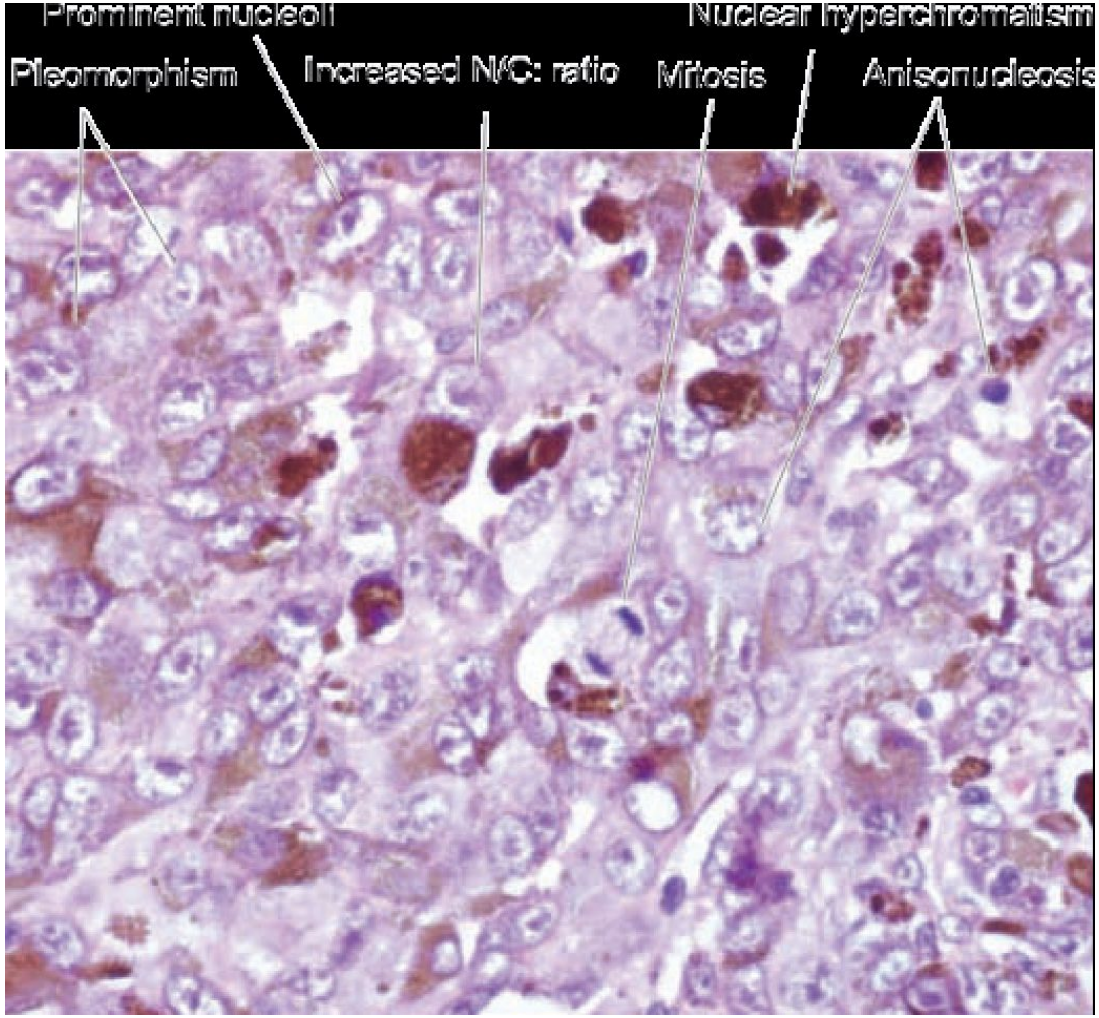
Prominent nucleoli
Nuclear hyperchromatism
Pleomorphism
Increased N/C: ratio
Mitosis
Anisonucleosis

Adenocarcinoma of the stomach. Irregular neoplastic glands infiltrate the gastric wall.

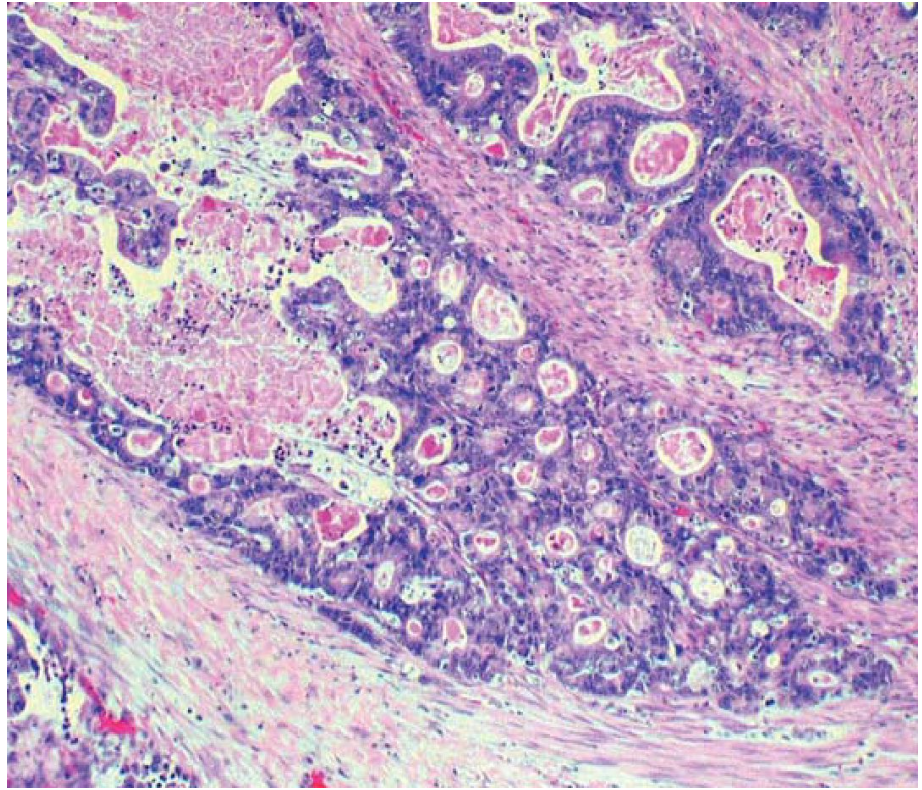

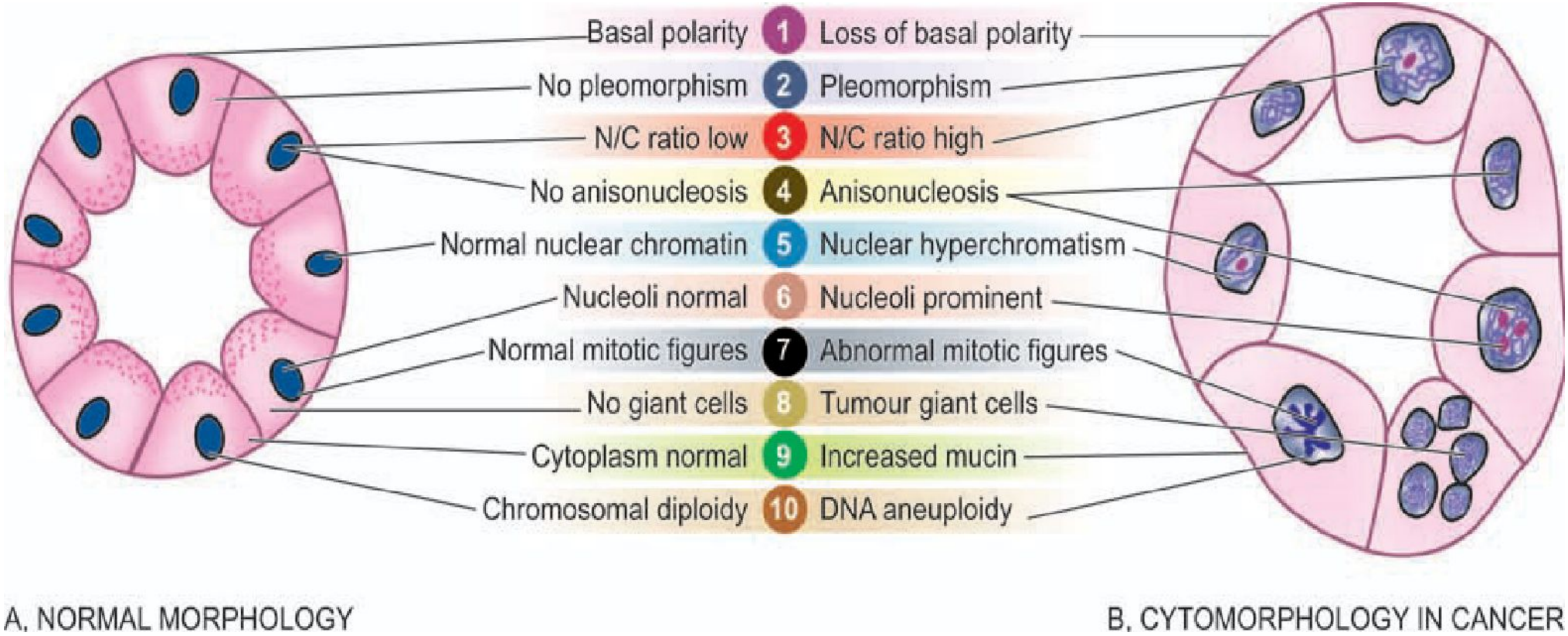
Basal polarity
1
Loss of basal polarity
No pleomorphism
2
Pleomorphism
N/C ratio low
3
N/C ratio high
No anisonucleosis
4
Anisonucleosis
Normal nuclear chromatin
5
Nuclear hyperchromatism
Nucleoli normal
6
Nucleoli prominent
Normal mitotic figures
7
Abnormal mitotic figures
No giant cells
8
Tumour giant cells
Cytoplasm normal
9
Increased mucin
Chromosomal diploidy
10
DNA aneuploidy
A. NORMAL MORPHOLOGY
B. CYTOMORPHOLOGY IN CANCER

BIPOLAR MITOSIS

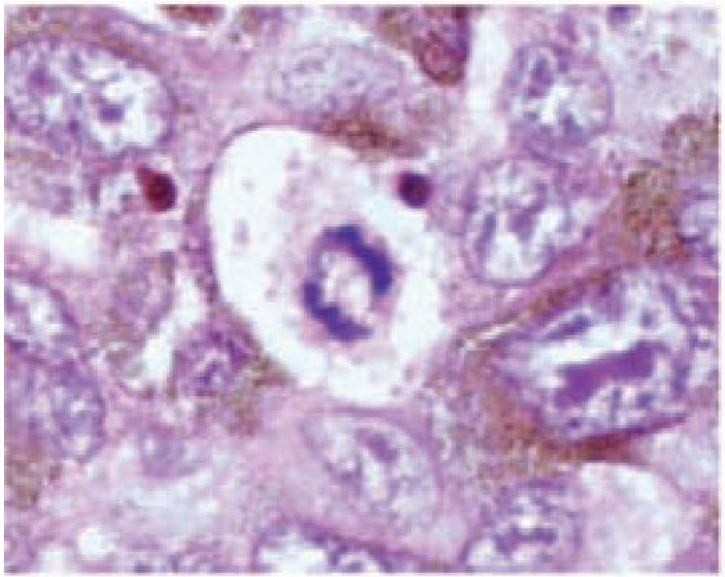

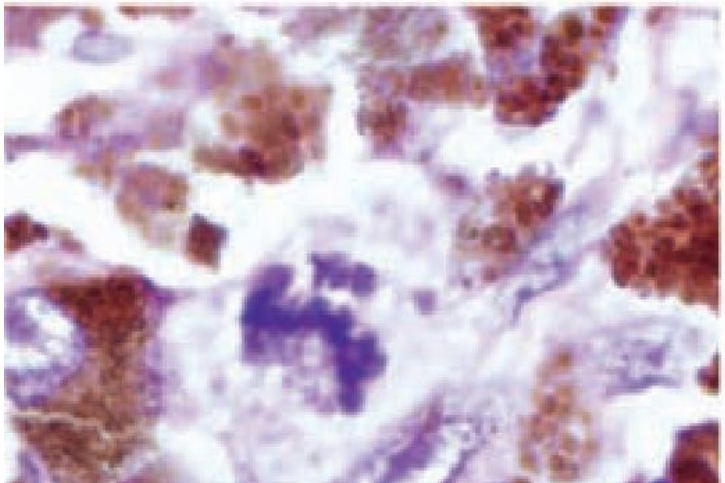

ABNORMAL MITOSIS

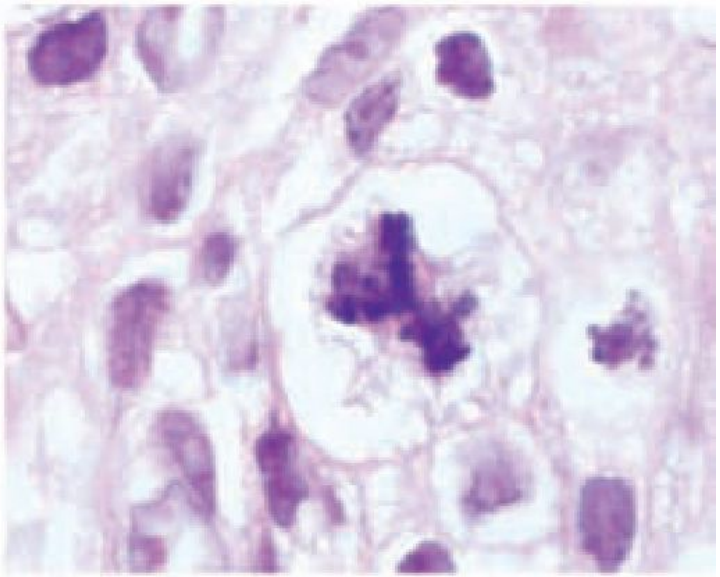

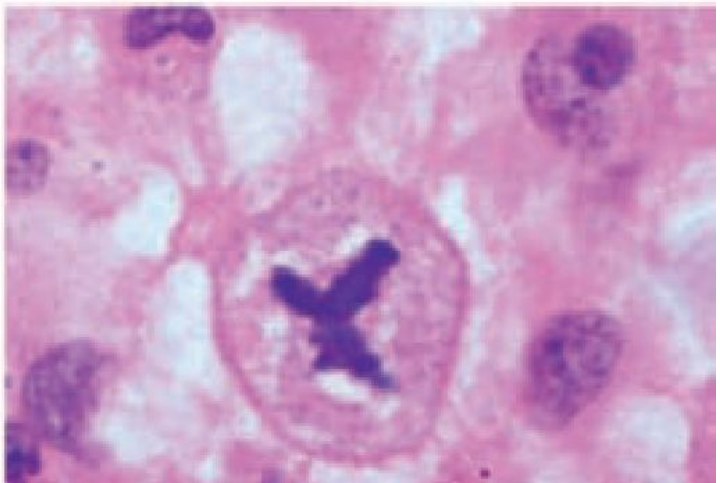

vii) Mitotic figures. The parenchymal cells of poorly differentiated tumours often show large number of mitoses as compared with benign tumours and well-differentiated malignant tumours. *Normal mitotic figures* may be seen in some non-neoplastic proliferating cells (e.g. haematopoietic cells of the bone marrow, intestinal epithelium, hepatocytes etc), in certain benign tumours and some low grade malignant tumours; in sections they are seen as a dark band of dividing chromatin at two poles of the nuclear spindle.

Abnormal or atypical mitotic figures are more important in malignant tumours and are identified as tripolar, quadripolar and multipolar spindles in malignant tumour cells.

viii) Tumour giant cells. Multinucleate tumour giant cells or giant cells containing a single large and bizarre nucleus,

ix) Functional (Cytoplasmic) changes. Structural anaplasia in tumours is accompanied with functional anaplasia as appreciated from the cytoplasmic constituents of the tumour cells.

Endocrine tumours may cause excessive hormone production leading to characteristic clinical syndromes.. This property of tumours is called *ectopic hormone production* e.g.oat cell carcinoma of the lung can secrete **ACTH and ADH;** less often it may produce gonadotropin, thyrotropin, parathormone, calcitonin and growth hormone. Ectopic erythropoietin may be produced by carcinoma of kidneys, hepatocellular carcinoma and cerebellar haemangioblastoma.

x) Chromosomal abnormalities. All tumour cells have abnormal genetic composition and on division they transmit the genetic abnormality to their progeny. Most malignant tumours show *DNA aneuploidy*, often in the form of an increase in the number of chromosomes, reflected morphologically by the increase in the size of nuclei. One of the most important examples of a consistent chromosomal abnormality in human malignancy is the presence of Philadelphia chromosome (named after the city in which it was first described) in 95% cases of chronic myeloid leukaemia. In this, part of the long arm of chromosome 9 is translocated to part of the long arm of chromosome 22 (t 9; 22). Other examples of neoplasms showing chromosomal abnormalities are translocation
Burkitt's lymphoma, acute lymphoid leukaemia, multiple myeloma, retinoblastoma, oat cell carcinoma, Wilms' tumour etc.

V. LOCAL INVASION (DIRECT SPREAD)

BENIGN TUMOURS.

Most benign tumours form encapsulated or circumscribed masses that *expand and push aside* the surrounding normal tissues without actually invading, infiltrating or metastasising.

MALIGNANT TUMOURS.

Malignant tumours also enlarge by expansion and some well-differentiated tumours may be partially encapsulated as well e.g. follicular carcinoma thyroid. But characteristically, they are distinguished from benign tumours by *invasion, infiltration and destruction* of the surrounding tissue, besides distant metastasis . In general, tumours invade via the route of least resistance, though eventually most cancers recognise no anatomic boundaries. Often, cancers extend through tissue spaces, permeate lymphatics, blood vessels, perineural spaces and may penetrate a bone by growing through nutrient foramina. More commonly, the tumours invade thin walled capillaries and veins than thick-walled arteries. Dense compact collagen, elastic tissue and cartilage are some of the tissues which are sufficiently resistant to invasion by tumours.

VI. METASTASIS (DISTANT SPREAD)

Metastasis (*meta* = transformation, *stasis* = residence) is defined as spread of tumour by invasion in such a way that discontinuous secondary tumour mass/masses are formed at the site of lodgement. *Metastasis and invasiveness are the two most important features to distinguish malignant from benign tumours:* benign tumours do not metastasise while all the malignant tumours with a few exceptions like gliomas of the central nervous system and basal cell carcinoma of the skin, can metastasise. Generally, larger, more aggressive and rapidly-growing tumours are more likely to metastasise but there are numerous exceptions. About one-third of malignant tumours at presentation have evident metastatic deposits while another 20% have occult metastasis.

Routes of Metastasis

Cancers may spread to distant sites by following pathways:

1. Lymphatic spread
2. Haematogenous spread
3. Spread along body cavities and natural passages (Transcoelomic spread, along epithelium-lined surfaces, spread via cerebrospinal fluid, implantation).

1. LYMPHATIC SPREAD.

In general, carcinomas metastasise by lymphatic route while sarcomas favour haematogenous route. However, sarcomas may also spread by lymphatic pathway.

The involvement of lymph nodes by malignant cells may be of two forms:

i) Lymphatic permeation.

The walls of lymphatics are readily invaded by cancer cells and may form a continuous growth in the lymphatic channels called lymphatic permeation.

ii) ***Lymphatic emboli***

Alternatively, the malignant cells may detach to form tumour emboli so as to be carried along the lymph to the next draining lymph node. The tumour emboli enter the lymph node at its convex surface and are lodged in the subcapsular sinus where they start growing Later, of course, the whole lymph node may be replaced and enlarged by the metastatic tumour , Generally, regional lymph nodes draining the tumour are invariably involved producing *regional nodal metastasis* e.g. from carcinoma breast to axillary lymph nodes, from carcinoma thyroid to lateral cervical lymph nodes, bronchogenic carcinoma to hilar and para-tracheal lymph nodes etc.

Important

Other times, due to obstruction of the lymphatics by tumour cells, the lymph flow is disturbed and tumour cells spread against the flow of lymph causing *retrograde metastases* at unusual sites e.g. metastasis of carcinoma prostate to the supraclavicular lymph nodes, metastatic deposits from bronchogenic carcinoma to the axillary lymph nodes.

Virchow's lymph node is nodal metastasis preferentially to supraclavicular lymph node from cancers of abdominal organs e.g. cancer stomach, colon, and gall bladder.

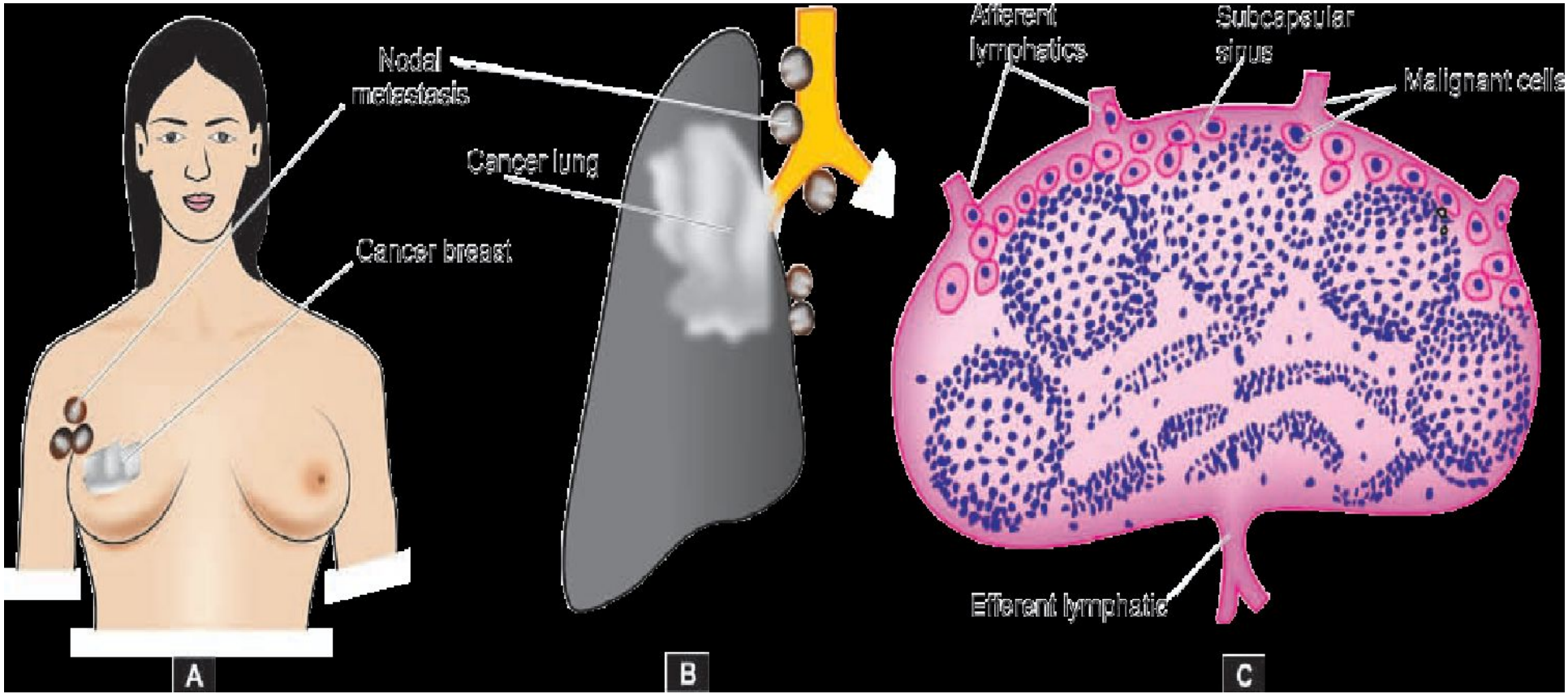
Nodal metastasis
Cancer breast
A
Cancer lung
B
Afferent lymphatics
Subcapsular sinus
Malignant cells
Efferent lymphatic
C

2. HAEMATOGENOUS SPREAD.

Blood-borne metastasis is the common route for sarcomas but certain carcinomas also frequently metastasise by this mode, especially those of the lung, breast, thyroid, kidney, liver, prostate and ovary. The sites where blood-borne metastasis commonly occurs are: the liver, lungs, brain, bones, kidney and adrenals, all of which provide 'good soil' for the growth of 'good seeds' (*seed-soil theory*). However, a few organs such as spleen, heart, and skeletal muscle generally do not allow tumour metastasis to grow. Spleen is unfavourable site due to open sinusoidal pattern which does not permit tumour cells to stay there long enough to produce metastasis. *Systemic veins* drain blood into vena cavae from limbs, head and neck and pelvis. Therefore, cancers of these sites more often metastasise to the lungs.

Portal veins drain blood from the bowel, spleen and pancreas into the liver. Thus, tumours of these organs frequently have secondaries in the liver.

Arterial spread of tumours is less likely because they are thick-walled and contain elastic tissue which is resistant to invasion. Nevertheless, arterial spread may occur when tumour cells pass through pulmonary capillary bed or through pulmonary arterial branches which have thin walls. Cancer of the lung may, *Retrograde spread* by blood route may occur at unusual sites due to retrograde spread after venous obstruction, just as with lymphatic metastases. Important examples are vertebral metastases in cancers of the thyroid and prostate.

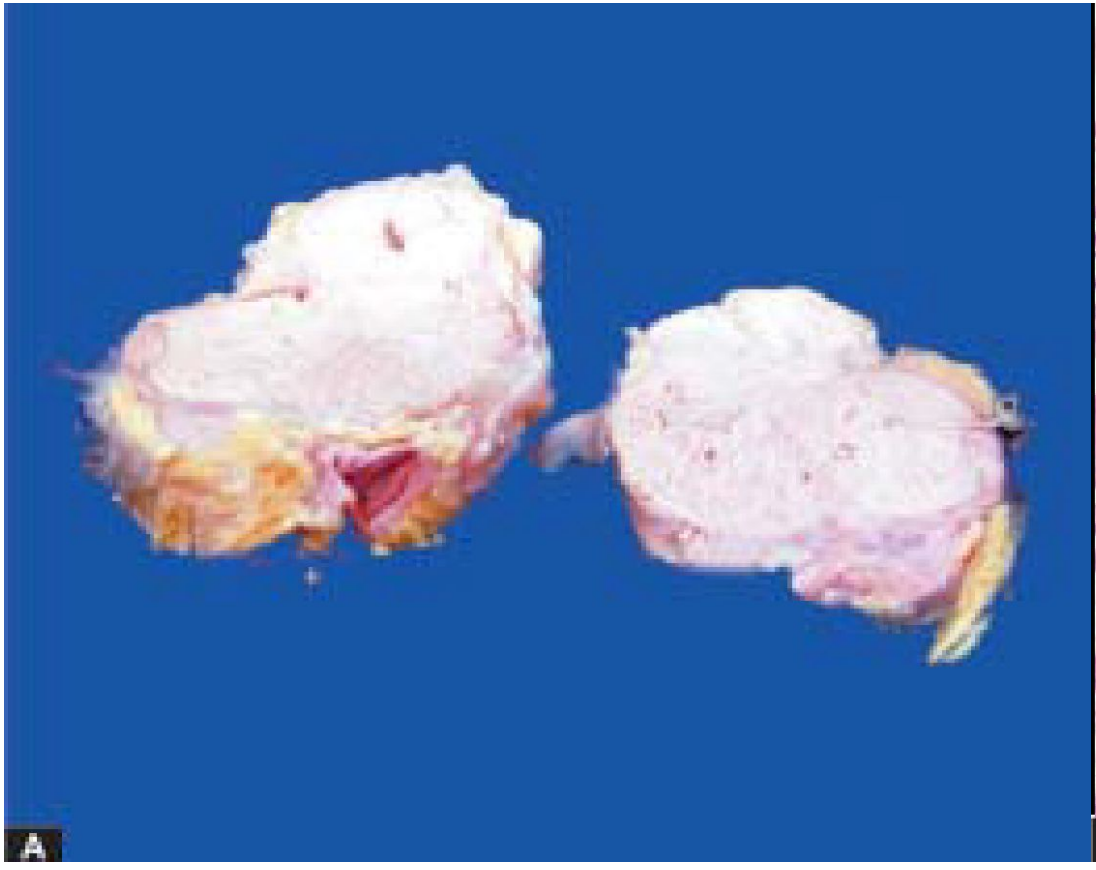
A

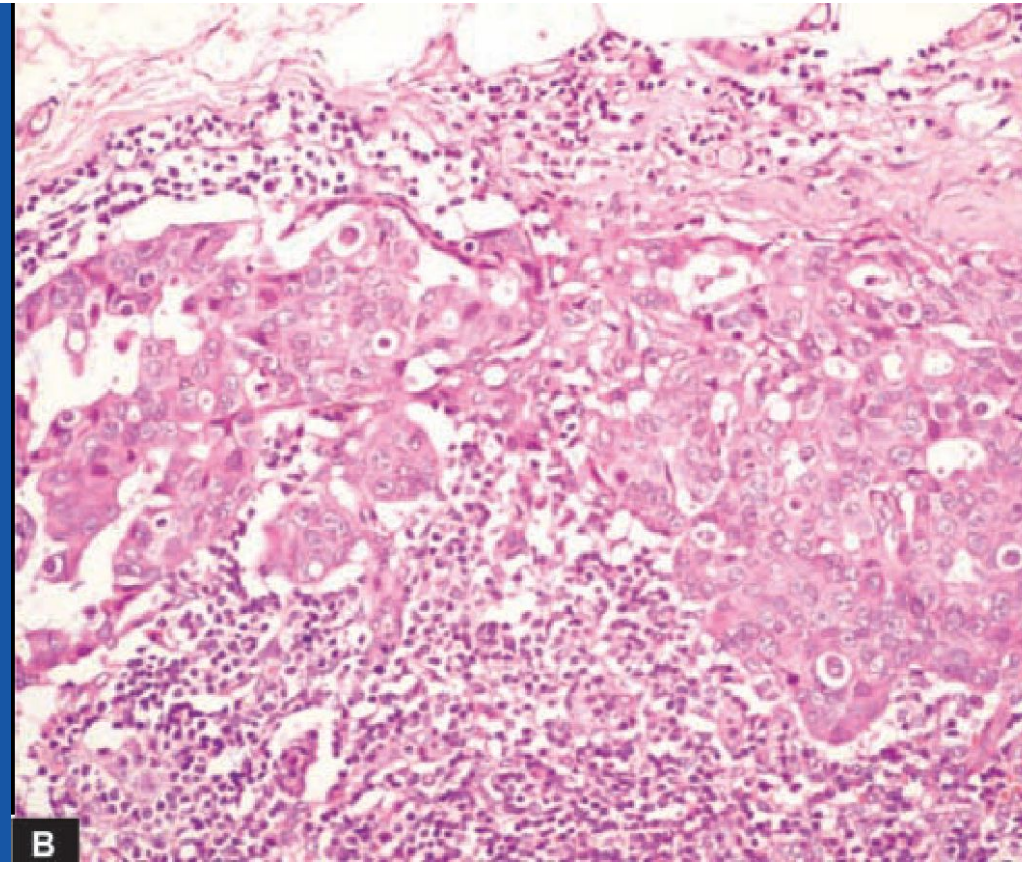
B

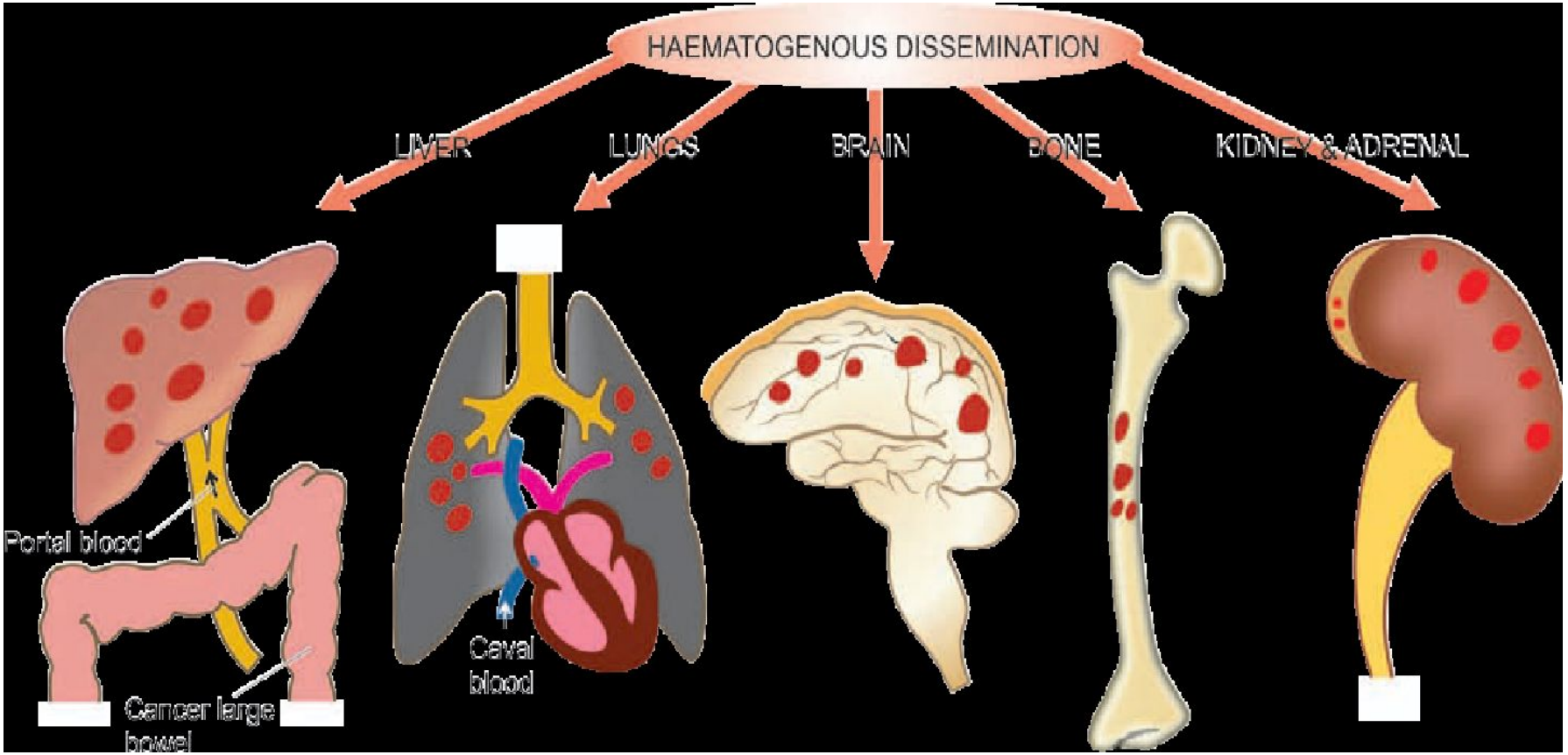
HAEMATOGENOUS DISSEMINATION
LIVER
LUNGS
BRAIN
BONE
KIDNEY & ADRENAL
Portal blood
Cancer large bowel
Caval blood

Dysplasia

Dysplasia is a term that literally means disordered growth. Dysplasia often occurs in metaplastic epithelium, but not all metaplastic epithelium is also dysplastic. Dysplastic cells exhibit considerable pleomorphism and often contain large hyperchromatic nuclei with a high nuclear to-cytoplasmic ratio. The architecture of the tissue may be disorderly.

Mitotic figures are more abundant than usual, although almost invariably they have a normal configuration.

When dysplastic changes are marked and involve the entire thickness of the epithelium but the lesion remains confined by the basement membrane, it is considered a preinvasive neoplasm and is referred to as carcinoma in situ.

Once the tumor cells breach the basement membrane, the tumor is said to be invasive. Dysplastic changes are often found adjacent to foci of invasive carcinoma, and in some situations, such as in long-term cigarette smokers and persons with Barrett esophagus, severe epithelial dysplasia frequently antedates the appearance of cancer. However, dysplasia does not necessarily progress to cancer. Mild to moderate changes that do not involve the entire thickness of epithelium may be reversible, and with removal of the inciting causes the epithelium may revert to normal. Even carcinoma in situ may take years to become invasive.

liver studded with metastatic cancer

- .

© Elsevier 2005